A 17-year-old girl with a history of depression is brought to the emergency department after attempting suicide. Her parents report that she consumed 2 bottles of insecticide after having an argument with her sister approximately 2 hours prior to presentation. The patient's symptoms include nausea, vomiting, abdominal pain, and copious watery diarrhea. She has a known history of self-cutting and suicidal ideations but no prior suicide attempts. Blood pressure is 86/42 mm Hg and pulse is 120/min. Her breath has a faint garlic odor, and she has numerous healing linear scars on her forearms. Which of the following medications should be administered immediately?

A. $CaNa_2EDTA$

B. Deferoxamine

C. Dimercaprol

D. Hydroxycobalamin

E. Methylene blue

Submit

A 17-year-old girl with a history of depression is brought to the emergency department after attempting suicide. Her parents report that she consumed 2 bottles of insecticide after having an argument with her sister approximately 2 hours prior to presentation. The patient's symptoms include nausea, vomiting, abdominal pain, and copious watery diarrhea. She has a known history of self-cutting and suicidal ideations but no prior suicide attempts. Blood pressure is 86/42 mm Hg and pulse is 120/min. Her breath has a faint garlic odor, and she has numerous healing linear scars on her forearms. Which of the following medications should be administered immediately?

- A. $CaNa_2EDTA$ (22%)
- B. Deferoxamine (8%)
- ✓ C. Dimercaprol (41%)
- D. Hydroxycobalamin (11%)
- E. Methylene blue (16%)

Omitted
Correct answer
C

41%
Answered correctly

30 secs
Time Spent

06/15/2020
Last Updated

Explanation

Arsenic poisoning	
Mechanism	• Binds to sulfhydryl groups • Disrupts **cellular respiration** & gluconeogenesis

Arsenic poisoning	
Mechanism	• Binds to sulfhydryl groups • Disrupts **cellular respiration** & gluconeogenesis
Sources	• Pesticides/insecticides • Contaminated water (often from wells) • Pressure-treated wood
Manifestations	• Acute: Garlic breath, vomiting, watery diarrhea, QTc prolongation • Chronic: Hypo/hyperpigmentation, hyperkeratosis, stocking-glove neuropathy
Treatment	• **Dimercaprol** (British anti-Lewisite) • DMSA (meso-2,3-dimercaptosuccinic acid, succimer)

©UWorld

Arsenic is odorless, tasteless, and easily absorbed after ingestion or inhalation. Toxicity can result from exposure to pesticides/insecticides, contaminated water, pressure-treated wood, metallurgy, mining, or glass-making. Arsenic **binds to sulfhydryl groups, impairing cellular respiration** via **inhibition of pyruvate dehydrogenase** and disruption of gluconeogenesis and glutathione metabolism.

Acute arsenic poisoning affects most organ systems and presents with abdominal pain, vomiting, **severe watery diarrhea**, delirium, and **hypotension** from dehydration. **QTc prolongation** can progress to life-threatening torsades de pointes. A **garlic odor** is often noted on the patient's breath or stool.

The first-line chelating agent is **dimercaprol** (eg, British Anti-Lewisite), which increases urinary excretion of heavy metals by forming stable, nontoxic soluble chelates. The sulfhydryl group of dimercaprol combines with arsenic and displaces arsenic ions from the sulfhydryl groups of

patient's breath or stool.

The first-line chelating agent is **dimercaprol** (eg, British Anti-Lewisite), which increases urinary excretion of heavy metals by forming stable, nontoxic soluble chelates. The sulfhydryl group of dimercaprol combines with arsenic and displaces arsenic ions from the sulfhydryl groups of enzymes involved in cellular respiration. Dimercaprol has a very narrow therapeutic index, and serious side effects include nephrotoxicity, hypertension, and fever.

(Choice A) Acute lead poisoning can present with constipation, anemia, and irritability and confusion. $CaNa_2EDTA$ is a treatment option for lead toxicity and works by forming non-ionizing salts to increase urinary lead excretion.

(Choice B) Deferoxamine is the preferred chelating agent for iron overdoses or overload due to multiple blood transfusions. It binds circulating iron and facilitates its urinary excretion.

(Choice D) Cyanide poisoning presents with confusion, flushing or a "cherry-red" skin color, abdominal pain, and vomiting. Its antidote, hydroxycobalamin (vitamin B_{12} precursor), binds to intracellular cyanide forming cyanocobalamin, which can be easily excreted in urine.

(Choice E) Methylene blue is indicated for treatment of methemoglobinemia, which presents with gray- or blue-colored skin, shortness of breath, and "chocolate-colored" blood. Methylene blue acts as an artificial electron transporter for reduction of methemoglobin through the NADPH pathway.

Educational objective:
Acute arsenic poisoning impairs cellular respiration and presents with abdominal pain, vomiting, diarrhea, hypotension, and a **garlic odor** on the breath. **Insecticides** and **contaminated water** are common sources of arsenic. **Dimercaprol** is the chelating agent of choice.

References

- Acute arsenic poisoning in two siblings.
- Homicidal arsenic poisoning.
- The role of chelation in the treatment of arsenic and mercury poisoning.

Pharmacology	Poisoning & Environmental Exposure	Arsenic poisoning
Subject	System	Topic

A 3-year-old, previously healthy boy is brought to the emergency department due to accidental drug ingestion. His mother found him playing with his grandfather's pill bottles earlier today, and later, he developed nausea and vomited twice. The patient also began breathing rapidly and appeared ill. His grandfather recently had a myocardial infarction and takes multiple medications. On physical examination, the patient is mildly lethargic, tachypneic, and tachycardic. The abdomen is soft and nontender. The extremities are warm and capillary refill time is normal. Laboratory studies reveal high anion gap metabolic acidosis. Treatment with intravenous sodium bicarbonate infusion is begun. This therapy is most likely to provide a beneficial effect via which of the following mechanisms?

A. Decreasing cardiotoxic effects of the drug

B. Decreasing charged form of the drug in plasma

C. Increasing drug trapping in the gastric lumen

D. Increasing excretion of the drug in the urine

E. Increasing hepatic drug glucuronidation

Submit

A 3-year-old, previously healthy boy is brought to the emergency department due to accidental drug ingestion. His mother found him playing with his grandfather's pill bottles earlier today, and later, he developed nausea and vomited twice. The patient also began breathing rapidly and appeared ill. His grandfather recently had a myocardial infarction and takes multiple medications. On physical examination, the patient is mildly lethargic, tachypneic, and tachycardic. The abdomen is soft and nontender. The extremities are warm and capillary refill time is normal. Laboratory studies reveal high anion gap metabolic acidosis. Treatment with intravenous sodium bicarbonate infusion is begun. This therapy is most likely to provide a beneficial effect via which of the following mechanisms?

A. Decreasing cardiotoxic effects of the drug (10%)

B. Decreasing charged form of the drug in plasma (22%)

C. Increasing drug trapping in the gastric lumen (4%)

✓ D. Increasing excretion of the drug in the urine (60%)

E. Increasing hepatic drug glucuronidation (1%)

Omitted
Correct answer
D

60%
Answered correctly

01 sec
Time Spent

03/23/2020
Last Updated

Explanation

This patient with **tachypnea** and anion gap metabolic acidosis following ingestion of an unknown substance most likely has acute **salicylate toxicity**. Salicylate is the active ingredient in aspirin, and it causes toxicity via stimulation of central respiratory drive and interference with cellular metabolism. Toxicity commonly presents with **tinnitus**, nausea, vomiting, and alteration in mental status ranging from irritability to lethargy or even coma. Patients classically have **primary respiratory alkalosis** and **primary anion gap metabolic acidosis**, a mixed disturbance that often

This patient with **tachypnea** and anion gap metabolic acidosis following ingestion of an unknown substance most likely has acute **salicylate toxicity**. Salicylate is the active ingredient in aspirin, and it causes toxicity via stimulation of central respiratory drive and interference with cellular metabolism. Toxicity commonly presents with **tinnitus**, nausea, vomiting, and alteration in mental status ranging from irritability to lethargy or even coma. Patients classically have **primary respiratory alkalosis** and **primary anion gap metabolic acidosis**, a mixed disturbance that often presents with blood pH near or within the normal range.

The toxicity of salicylate is caused mostly by its protonated, **salicylic acid** form (Sal-H), which is **lipophilic** and readily **passes into the tissues**. Therefore, **sodium bicarbonate** helps treat salicylate toxicity in 2 ways:

- The bicarbonate acts as a base to bind free hydrogen ions in the blood. This facilitates the conversion of lipophilic salicylic acid to a lipophobic salicylate ion (Sal^-), trapping much of the compound within the bloodstream.
- The bicarbonate also alkalinizes the urine to facilitate the conversion of salicylate and its metabolites to their lipophobic, ionized form, which reduces renal tubular reabsorption of the compounds and **increases urinary excretion**.

Notably, acetazolamide is contraindicated in acute salicylate toxicity because it alkalinizes the urine at the expense of acidifying the blood (sodium bicarbonate alkalinizes both the blood and urine), which facilitates additional tissue absorption of salicylic acid.

(Choice A) Sodium bicarbonate is used to reduce the cardiotoxic effects of tricyclic antidepressant (TCA) overdose by decreasing the binding of TCAs to cardiac sodium channels and lowering the risk of arrhythmia.

(Choice B) Sodium bicarbonate facilitates conversion to the salicylate ion (Sal^-), increasing, not decreasing, the amount of charged compound in the blood.

(Choice C) Activated charcoal is commonly given orally to patients with acute salicylate toxicity because it binds to salicylate in the gastric lumen and prevents absorption of the drug. Sodium bicarbonate is given intravenously and acts within the bloodstream and urine.

(Choice E) Salicylate is metabolized mostly via hepatic glucuronidation; however, the induction of hepatic glucuronidation is not used to treat toxicity.

Educational objective:
Salicylate toxicity typically presents with mixed primary respiratory alkalosis and anion gap metabolic acidosis. Sodium bicarbonate facilitates

lipophobic salicylate ion (Sal^-), trapping much of the compound within the bloodstream.

- The bicarbonate also alkalinizes the urine to facilitate the conversion of salicylate and its metabolites to their lipophobic, ionized form, which reduces renal tubular reabsorption of the compounds and **increases urinary excretion**.

Notably, acetazolamide is contraindicated in acute salicylate toxicity because it alkalinizes the urine at the expense of acidifying the blood (sodium bicarbonate alkalinizes both the blood and urine), which facilitates additional tissue absorption of salicylic acid.

(Choice A) Sodium bicarbonate is used to reduce the cardiotoxic effects of tricyclic antidepressant (TCA) overdose by decreasing the binding of TCAs to cardiac sodium channels and lowering the risk of arrhythmia.

(Choice B) Sodium bicarbonate facilitates conversion to the salicylate ion (Sal^-), increasing, not decreasing, the amount of charged compound in the blood.

(Choice C) Activated charcoal is commonly given orally to patients with acute salicylate toxicity because it binds to salicylate in the gastric lumen and prevents absorption of the drug. Sodium bicarbonate is given intravenously and acts within the bloodstream and urine.

(Choice E) Salicylate is metabolized mostly via hepatic glucuronidation; however, the induction of hepatic glucuronidation is not used to treat toxicity.

Educational objective:
Salicylate toxicity typically presents with mixed primary respiratory alkalosis and anion gap metabolic acidosis. Sodium bicarbonate facilitates conversion to the lipophobic, ionized form of salicylate (Sal^-), which traps much of the compound in the bloodstream and increases its urinary excretion.

References

- Guidance document: Management priorities in salicylate toxicity.

Pharmacology	Poisoning & Environmental Exposure	Salicylate poisoning
Subject	System	Topic

Copyright © UWorld. All rights reserved.

A 42-year-old man is brought to the emergency department due to nausea, vomiting, and blurred vision. He was making his own whiskey with a home moonshine still and started feeling sick after sampling the first several ounces of distillate. Funduscopic evaluation reveals optic disc hyperemia. Laboratory results show a high anion gap metabolic acidosis. It is determined that the patient's symptoms are due to enzymatic conversion of methanol into formate by alcohol dehydrogenase. He is started on fomepizole, a medication that transiently binds to alcohol dehydrogenase and prevents methanol from accessing the enzyme's active site. Which of the following graphs most accurately portrays the change in enzyme kinetics after administration of the antidote?

(Black curves = before treatment)

A.

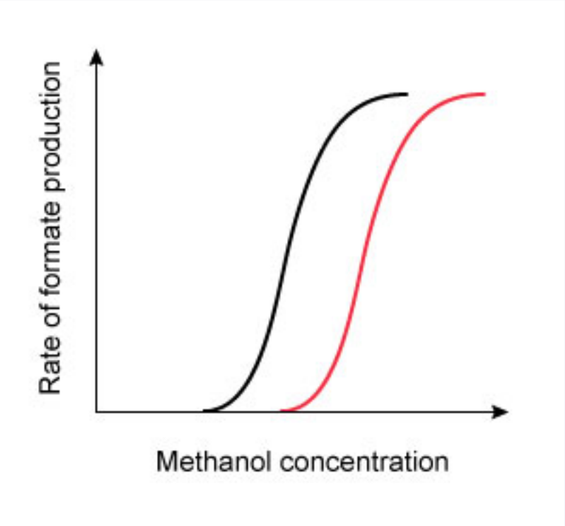

B.

B.

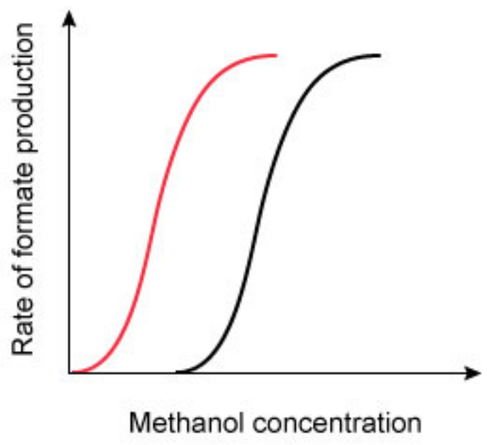
Rate of formate production
Methanol concentration

C.

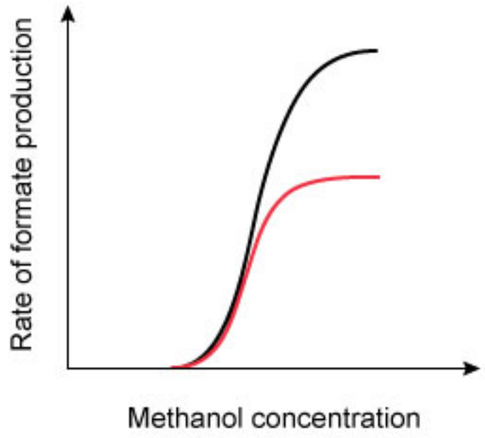
Rate of formate production
Methanol concentration

D.

D.

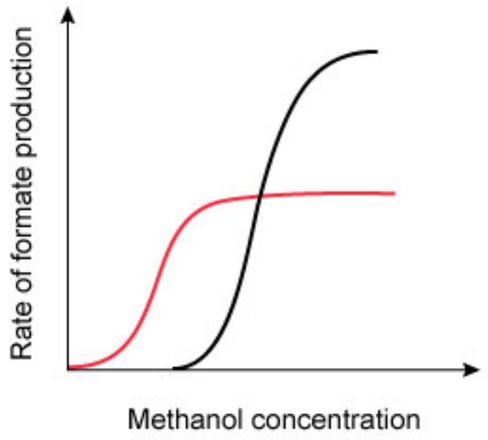
Rate of formate production
Methanol concentration

E.

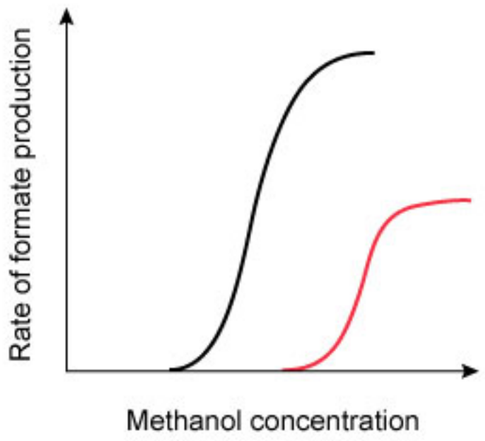
Rate of formate production
Methanol concentration

Submit

A. (57%)

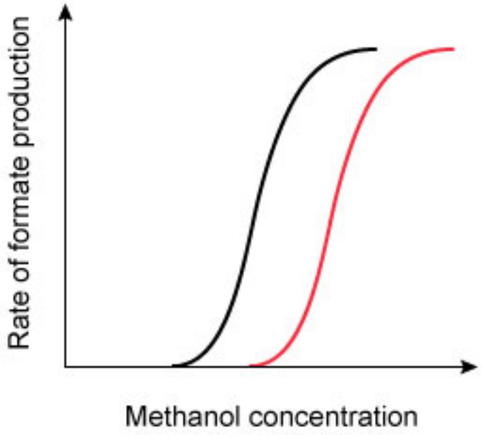
Rate of formate production
Methanol concentration

B. (6%)

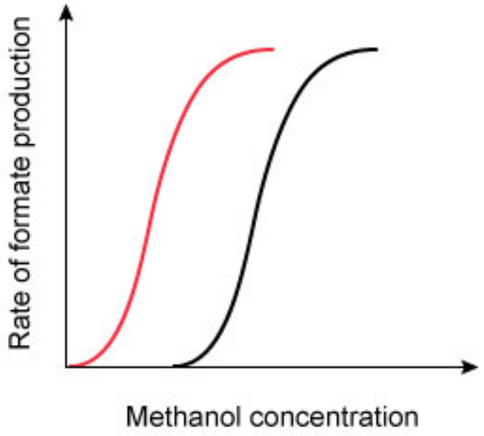
Rate of formate production
Methanol concentration

C. (19%)

C. (19%)

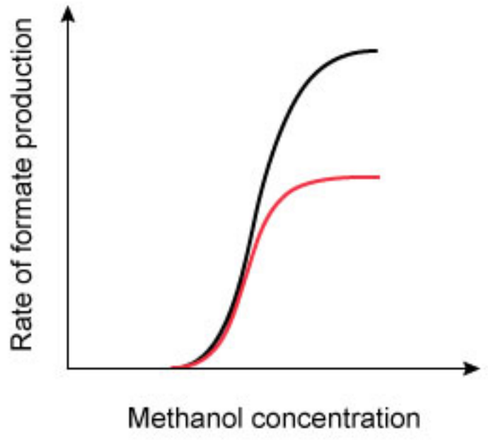
Rate of formate production
Methanol concentration

D. (5%)

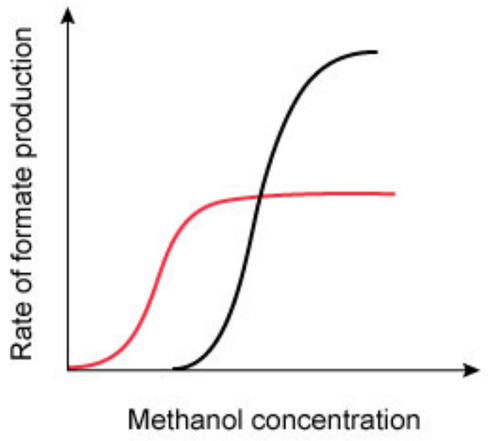
Rate of formate production
Methanol concentration

E. (10%)

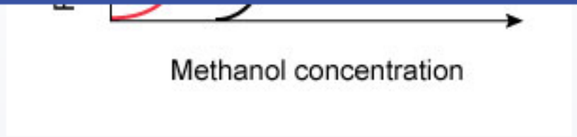

E. (10%)

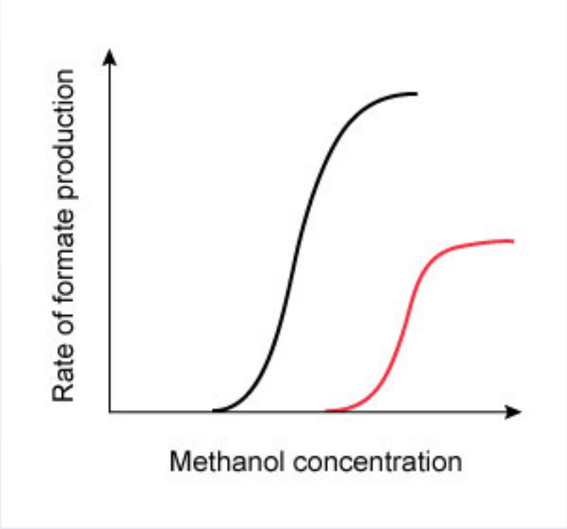

Omitted
Correct answer
A

57%
Answered correctly

07 secs
Time Spent

01/27/2020
Last Updated

Explanation

Explanation

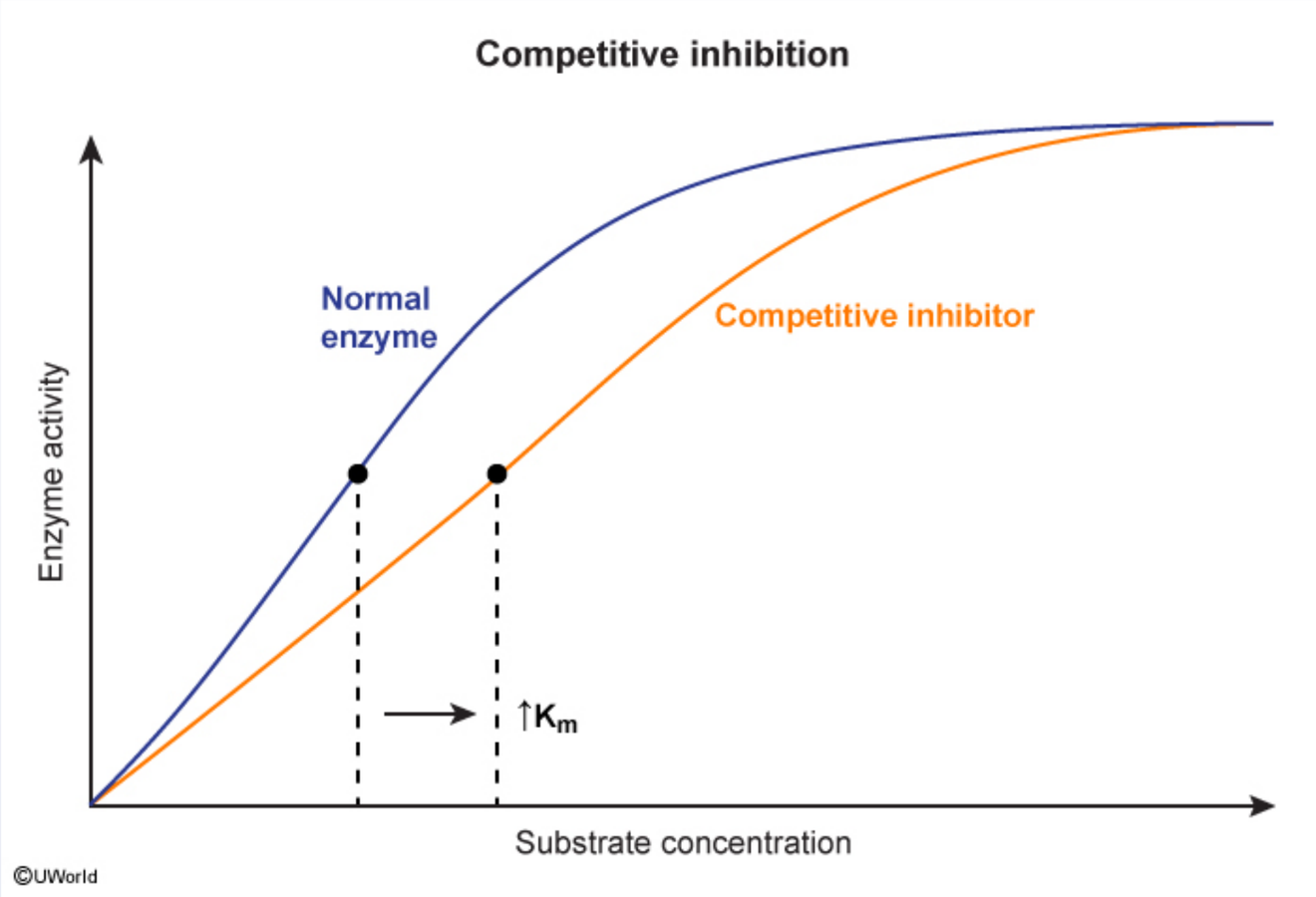

Methanol itself is relatively nontoxic, primarily causing CNS depression similar to that caused by ethanol. However, once ingested, methanol is converted by alcohol and aldehyde dehydrogenase into **formate**, a metabolite with pronounced **nervous system toxicity** (eg, optic nerve destruction, basal ganglia hemorrhage).

Treatment of methanol intoxication is targeted at reducing formate production by inhibiting alcohol dehydrogenase. **Fomepizole** is a **competitive inhibitor of alcohol dehydrogenase** that decreases the conversion rate of methanol into formate. Ethanol can also be used as a competitive

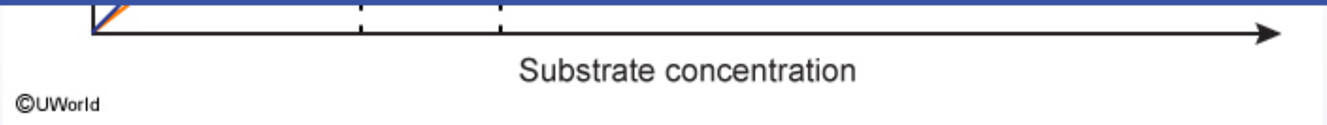

Methanol itself is relatively nontoxic, primarily causing CNS depression similar to that caused by ethanol. However, once ingested, methanol is converted by alcohol and aldehyde dehydrogenase into **formate**, a metabolite with pronounced **nervous system toxicity** (eg, optic nerve destruction, basal ganglia hemorrhage).

Treatment of methanol intoxication is targeted at reducing formate production by inhibiting alcohol dehydrogenase. **Fomepizole** is a **competitive inhibitor of alcohol dehydrogenase** that decreases the conversion rate of methanol into formate. Ethanol can also be used as a competitive inhibitor, although it is less preferred due to difficulty in dosing.

Competitive inhibition occurs when an inhibitor binds to an enzyme (usually at the active site), preventing it from binding the substrate. Because competitive inhibitors compete with the substrate for binding to the active site, higher substrate concentrations are required to reach ½ V_{max}, thereby **increasing apparent K_m**. However, competitive inhibitors do not alter enzyme function directly, therefore **V_{max} is unchanged**.

(Choice B) This graph shows decreased K_m (ie, increased substrate affinity) after treatment, which would increase the toxicity of methanol.

(Choices C, D, and E) These graphs show a decrease in V_{max} (ie, decreased maximum reaction rate) which does not occur with competitive inhibition. Decreased V_{max} occurs with the use of noncompetitive and mixed inhibitors that bind allosterically to an enzyme; noncompetitive inhibitors do not change the Km, whereas mixed inhibitors can either raise or lower the K_m.

Educational objective:
Methanol and ethylene glycol have relatively little direct toxicity (similar to ethanol) but are metabolized into highly toxic compounds by alcohol and aldehyde dehydrogenase. Treatment involves administration of fomepizole, a competitive inhibitor of alcohol dehydrogenase (increases K_m without reducing V_{max}).

Pharmacology	Poisoning & Environmental Exposure	Agonism and antagonism
Subject	System	Topic

Copyright © UWorld. All rights reserved.

A 40-year-old woman is brought to the emergency department due to difficulty breathing and muscle weakness. She was one of several people who developed symptoms in a movie theater. Temperature is 36.7 C (98.1 F), blood pressure is 112/62 mm Hg, pulse is 51/min, and respirations are 24/min. On physical examination, the patient is diaphoretic. The pupils are pinpoint and unreactive, and significant tearing is noted. Diffuse rhonchi and wheezing are present in the lungs bilaterally. Muscle strength is diminished throughout, and fasciculations are noted in the extremities. First-line therapy is administered, but the patient remains weak. Treatment with which of the following is most likely to improve this patient's current conditon?

A. Diphenhydramine

B. Hemodialysis

C. Hyperbaric oxygen

D. Physostigmine

E. Pralidoxime

Submit

A 40-year-old woman is brought to the emergency department due to difficulty breathing and muscle weakness. She was one of several people who developed symptoms in a movie theater. Temperature is 36.7 C (98.1 F), blood pressure is 112/62 mm Hg, pulse is 51/min, and respirations are 24/min. On physical examination, the patient is diaphoretic. The pupils are pinpoint and unreactive, and significant tearing is noted. Diffuse rhonchi and wheezing are present in the lungs bilaterally. Muscle strength is diminished throughout, and fasciculations are noted in the extremities. First-line therapy is administered, but the patient remains weak. Treatment with which of the following is most likely to improve this patient's current conditon?

A. Diphenhydramine (4%)

B. Hemodialysis (2%)

C. Hyperbaric oxygen (7%)

D. Physostigmine (19%)

✓ E. Pralidoxime (67%)

Omitted
Correct answer
E

67%
Answered correctly

01 sec
Time Spent

03/13/2020
Last Updated

Explanation

Organophosphate poisoning	
Common exposures	• Pesticide: farmer/field worker, pediatric ingestion, suicide attempt • Nerve agent: multiple patients presenting with similar symptoms

Organophosphate poisoning	
Common exposures	• Pesticide: farmer/field worker, pediatric ingestion, suicide attempt • Nerve agent: multiple patients presenting with similar symptoms

Manifestations	• Muscarinic:
	  ◦ **D**iarrhea/diaphoresis
	  ◦ **U**rination
	  ◦ **M**iosis
	  ◦ **B**ronchospasms, bronchorrhea, bradycardia
	  ◦ **E**mesis
	  ◦ **L**acrimation
	  ◦ **S**alivation
	• Nicotinic: muscle weakness, paralysis, fasciculations

Management	• Decontamination • Atropine reverses muscarinic symptoms • Pralidoxime reverses nicotinic and muscarinic symptoms (reactivates cholinesterase)

This patient with bradycardia, miosis, diaphoresis, excessive secretions (eg, bronchorrhea, tearing), and weakness with fasciculations has signs of **cholinergic toxicity**. Most cases of cholinergic toxicity are due to **organophosphate** pesticides. However, the occurrence in multiple patients in a city setting suggests intentional organophosphate exposure, possibly due to a chemical weapon (eg, sarin, soman).

Organophosphates **inhibit acetylcholinesterase** in the muscarinic and nicotinic cholinergic synapses, leading to decreased acetylcholine degradation and overstimulation of the corresponding receptors. In addition to widespread increased visceral smooth muscle tone and glandular secretions due to muscarinic hyperactivity (mnemonic: DUMBELS), **nicotinic hyperactivity** causes **muscle weakness** and paralysis that can lead to rapid respiratory depression and death.

Initial management of organophosphate toxicity includes atropine, a competitive inhibitor of acetylcholine at the muscarinic receptor, which relieves muscarinic hyperstimulation. However, atropine does not have activity at the nicotinic receptors and cannot treat neuromuscular dysfunction. Therefore, **pralidoxime**, a **cholinesterase-reactivating agent** that works at both nicotinic and muscarinic sites, should be administered to any

secretions due to muscarinic hyperactivity (mnemonic: DUMBELS), **nicotinic hyperactivity** causes **muscle weakness** and paralysis that can lead to rapid respiratory depression and death.

Initial management of organophosphate toxicity includes atropine, a competitive inhibitor of acetylcholine at the muscarinic receptor, which relieves muscarinic hyperstimulation. However, atropine does not have activity at the nicotinic receptors and cannot treat neuromuscular dysfunction. Therefore, **pralidoxime**, a **cholinesterase-reactivating agent** that works at both nicotinic and muscarinic sites, should be administered to any patient with neuromuscular dysfunction (eg, weakness, fasciculations). It should be given only **after atropine** because pralidoxime can cause transient acetylcholinesterase inhibition, which can momentarily worsen symptoms.

(Choice A) Diphenhydramine is an inverse agonist of the histamine H1 receptor, which allows it to function as an antihistamine. Because the H1 receptor is similar to the muscarinic receptor, diphenhydramine has some antimuscarinic effects (eg, urinary retention). However, it is less potent than atropine, and it would not reverse nicotinic dysfunction (weakness).

(Choice B) Hemodialysis is sometimes used to treat toxic alcohol poisoning, which usually presents with altered mental status, as well as vision changes (methanol) or flank pain and hematuria (ethylene glycol). It is not indicated in cholinergic toxicity.

(Choice C) Hyperbaric oxygen is used to treat severe carbon monoxide poisoning, which presents with nausea, dizziness, and altered mental status. Patients typically have cherry-red cheeks and lips.

(Choice D) Physostigmine is an acetylcholinesterase inhibitor that is sometimes used to treat anticholinergic toxicity (ie, flushing, mydriasis, anhidrosis, fever, urinary retention). It would worsen this patient's symptoms.

Educational objective:
Organophosphates inhibit acetylcholinesterase, leading to symptoms of muscarinic (mnemonic: DUMBELS) and nicotinic (neuromuscular dysfunction) cholinergic hyperstimulation. Management includes atropine, a competitive inhibitor of acetylcholine at the muscarinic receptor (reverses muscarinic symptoms), followed by pralidoxime, a cholinesterase-reactivating agent that treats both nicotinic and muscarinic symptoms.

Pharmacology	Poisoning & Environmental Exposure	Organophosphate poisoning
Subject	System	Topic

Copyright © UWorld. All rights reserved.

A 24-year-old woman comes to the emergency department due to bloody emesis. She had 2 episodes of vomiting bright red blood and feels lightheaded and dizzy. The patient was recently diagnosed with factitious disorder after being hospitalized multiple times for a myriad of symptoms and undergoing several invasive procedures. Physical examination shows scattered ecchymoses. The abdomen is soft and nontender. Rectal examination shows maroon-colored, guaiac-positive stool. After much questioning, she admits to having ingested rat poison several days ago. Immediate treatment of this patient should include which of the following?

A. Cryoprecipitate

B. Desmopressin

C. Fresh frozen plasma

D. Platelet transfusion

E. Protamine sulfate

Submit

A 24-year-old woman comes to the emergency department due to bloody emesis. She had 2 episodes of vomiting bright red blood and feels lightheaded and dizzy. The patient was recently diagnosed with factitious disorder after being hospitalized multiple times for a myriad of symptoms and undergoing several invasive procedures. Physical examination shows scattered ecchymoses. The abdomen is soft and nontender. Rectal examination shows maroon-colored, guaiac-positive stool. After much questioning, she admits to having ingested rat poison several days ago. Immediate treatment of this patient should include which of the following?

A. Cryoprecipitate (7%)

B. Desmopressin (2%)

✓ C. Fresh frozen plasma (68%)

D. Platelet transfusion (8%)

E. Protamine sulfate (12%)

Omitted
Correct answer
C

68%
Answered correctly

01 sec
Time Spent

06/22/2020
Last Updated

Explanation

	Warfarin overdose	Heparin overdose
Vitamin K	Effective (takes days)	Ineffective

	Warfarin overdose	Heparin overdose
Vitamin K	Effective (takes days)	Ineffective
FFP	Effective (contains all blood clotting factors & proteins)	Ineffective (contains antithrombin III → enhances heparin effect)
Protamine	Ineffective	Effective (heparin-specific antidote)

FFP = fresh frozen plasma.

©UWorld

Most available **rodenticides** contain brodifacoum ("superwarfarin"), a long-acting 4-hydroxycoumarin derivative. By ingesting rodenticide, this patient depleted her vitamin K-dependent clotting factors, thereby causing an acquired coagulopathy (similar to **warfarin** toxicity) that led to bleeding (gastrointestinal hemorrhage with hematemesis and guaiac-positive stools, ecchymoses). The anticoagulant effect is generally seen approximately 48 hours following ingestion, which represents the time required for depletion of the coagulation factors.

To treat life-threatening bleeding in the setting of coumarin or warfarin toxicity, rapid replenishment of clotting factors II, VII, IX, and X is generally performed through intravenous administration of **fresh frozen plasma** (FFP), which contains all coagulation factors and other proteins present in the original unit of blood. Additional vitamin K should also be given. Vitamin K alone can be used in patients with abnormal coagulation tests (eg, prolonged prothrombin or partial thromboplastin times) but no bleeding.

(Choice A) Cryoprecipitate (precipitate obtained from FFP by centrifugation/thawing) contains factor VIII, factor XIII, von Willebrand factor, and fibrinogen. Therefore, it would not be of significant benefit when vitamin K-dependent clotting factors (II, VII, IX, and X) require replenishment.

(Choice B) Desmopressin increases plasma levels of von Willebrand factor and factor VIII; it is used in management of hemophilia A and von Willebrand disease.

(Choice D) Rat poison or warfarin does not affect platelet count.

(Choice E) Protamine sulfate is used to treat heparin overdose. It binds to heparin, forming a complex that has no anticoagulant activity.

FFP = fresh frozen plasma.

©UWorld

Most available **rodenticides** contain brodifacoum ("superwarfarin"), a long-acting 4-hydroxycoumarin derivative. By ingesting rodenticide, this patient depleted her vitamin K-dependent clotting factors, thereby causing an acquired coagulopathy (similar to **warfarin** toxicity) that led to bleeding (gastrointestinal hemorrhage with hematemesis and guaiac-positive stools, ecchymoses). The anticoagulant effect is generally seen approximately 48 hours following ingestion, which represents the time required for depletion of the coagulation factors.

To treat life-threatening bleeding in the setting of coumarin or warfarin toxicity, rapid replenishment of clotting factors II, VII, IX, and X is generally performed through intravenous administration of **fresh frozen plasma** (FFP), which contains all coagulation factors and other proteins present in the original unit of blood. Additional vitamin K should also be given. Vitamin K alone can be used in patients with abnormal coagulation tests (eg, prolonged prothrombin or partial thromboplastin times) but no bleeding.

(Choice A) Cryoprecipitate (precipitate obtained from FFP by centrifugation/thawing) contains factor VIII, factor XIII, von Willebrand factor, and fibrinogen. Therefore, it would not be of significant benefit when vitamin K-dependent clotting factors (II, VII, IX, and X) require replenishment.

(Choice B) Desmopressin increases plasma levels of von Willebrand factor and factor VIII; it is used in management of hemophilia A and von Willebrand disease.

(Choice D) Rat poison or warfarin does not affect platelet count.

(Choice E) Protamine sulfate is used to treat heparin overdose. It binds to heparin, forming a complex that has no anticoagulant activity.

Educational objective:
Most available rodenticides contain brodifacoum, a long-acting 4-hydroxycoumarin derivative. A patient who has ingested a quantity of rodenticide sufficient to cause coagulopathy and abnormal bleeding (similar to warfarin toxicity) requires immediate treatment with fresh frozen plasma in addition to vitamin K.

Pharmacology	Poisoning & Environmental Exposure	Anticoagulants
Subject	System	Topic

Copyright © UWorld. All rights reserved.

A 20-year-old man is brought to the emergency department after being found confused and somnolent in his apartment. His face and upper body are covered with emesis. The patient was last seen with a normal appearance 4 hours ago. Medical history is significant for excessive alcohol use. Temperature is 36.8 C (98.2 F), blood pressure is 120/88 mm Hg, pulse is 102/min, and respirations are 26/min. The patient is barely rousable and does not answer questions. Cardiopulmonary examination is normal. The abdomen is soft and nontender. There are no focal findings on neurologic examination. Laboratory results are as follows:

Serum chemistry	
Sodium	136 mEq/L
Chloride	91 mEq/L
Bicarbonate	6 mEq/L
Urea nitrogen	22 mg/dL
Creatinine	1.9 mg/dL
Glucose	80 mg/dL
Lactic acid	normal
Serum osmolality	380 mOsm/kg
Arterial blood gas (on room air)	
pH	7.19
PO_2	110 mm Hg
PCO_2	20 mm Hg

Acute poisoning is suspected and the patient is given an appropriate antidote. Which of the following is the most likely mechanism of action of the antidote?

Urea nitrogen	22 mg/dL
Creatinine	1.9 mg/dL
Glucose	80 mg/dL
Lactic acid	normal
Serum osmolality	380 mOsm/kg
Arterial blood gas (on room air)	
pH	7.19
PO_2	110 mm Hg
PCO_2	20 mm Hg

Acute poisoning is suspected and the patient is given an appropriate antidote. Which of the following is the most likely mechanism of action of the antidote?

A. Binds to the poison in the blood to form an inert complex

B. Competitively binds to cell surface receptors

C. Decreases the conversion rate of poison into a toxic metabolite

D. Prevents the gastrointestinal absorption of poison into the body

E. Promotes rapid enzyme-dependent detoxification in the liver

Submit

Urea nitrogen	22 mg/dL
Creatinine	1.9 mg/dL
Glucose	80 mg/dL
Lactic acid	normal
Serum osmolality	380 mOsm/kg
Arterial blood gas (on room air)	
pH	7.19
PO_2	110 mm Hg
PCO_2	20 mm Hg

Acute poisoning is suspected and the patient is given an appropriate antidote. Which of the following is the most likely mechanism of action of the antidote?

A. Binds to the poison in the blood to form an inert complex (8%)

B. Competitively binds to cell surface receptors (9%)

✓ C. Decreases the conversion rate of poison into a toxic metabolite (63%)

D. Prevents the gastrointestinal absorption of poison into the body (7%)

E. Promotes rapid enzyme-dependent detoxification in the liver (10%)

Omitted
Correct answer

63%
Answered correctly

05 secs
Time Spent

02/11/2020
Last Updated

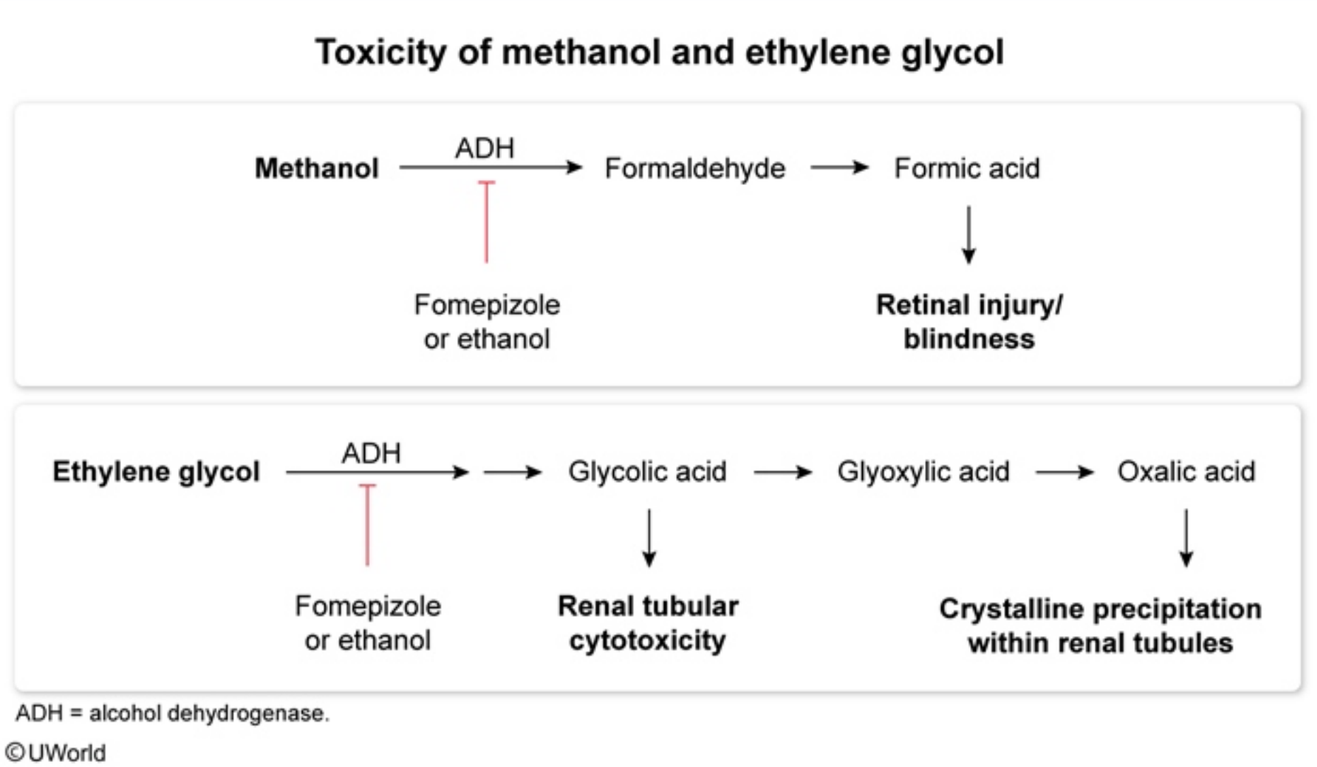

This patient has altered mental status, acute renal failure, anion gap metabolic acidosis (AGMA) with normal glucose and lactate levels, and a markedly elevated osmolar gap. These findings are highly suggestive of toxic alcohol ingestion, likely with ethylene glycol (although methanol ingestion is difficult to rule out in this obtunded patient).

Ethylene glycol and methanol are central nervous system depressants found in antifreeze and cleaning solutions, and may be accidentally or intentionally ingested (eg, substitute for ethanol in patients with dependency, suicide attempt). Although the parent alcohols are relatively nontoxic, ethylene glycol and methanol exhibit profoundly toxic effects when metabolized:

- **Ethylene glycol** metabolites (eg, oxalic acid, glycolic acid, glyoxylic acid) cause **acute kidney injury** due to cytotoxicity and crystalline obstruction.

Fomepizole or ethanol

Retinal injury/ blindness

Et

ADH =

©UWo

This patient has altered m
markedly elevated osmola
ingestion is difficult to rule

Ethylene glycol and metha
intentionally ingested (eg,
ethylene glycol and metha

- **Ethylene glycol** me
obstruction.
- **Methanol** metabolit

Fomepizole, a **competiti**
By inhibiting the first step
Alternately, ethanol is som
required.

oxic,

Exhibit Display

Anion gap metabolic acidosis	
Calculation	Anion gap = sodium – (chloride + bicarbonate) (Normal: 10-14)
Common causes Mnemonic: MUDPILES	• Methanol • Uremia • Diabetic ketoacidosis • Propylene glycol/paraldehyde • Isoniazid/iron • Lactic acidosis • Ethylene glycol (antifreeze) • Salicylates (aspirin)

Add To New Card | Existing Card

Fomepizole or ethanol

Retinal injury/ blindness

Et

ADH =

©UWo

This patient has altered m
markedly elevated osmola
ingestion is difficult to rule

Ethylene glycol and metha
intentionally ingested (eg,
ethylene glycol and metha

- **Ethylene glycol** me
obstruction.
- **Methanol** metabolit

Fomepizole, a **competiti**
By inhibiting the first step
Alternately, ethanol is som
required.

oxic,

y.

Exhibit Display

Toxic alcohols		
Toxicity	**Clinical features**	**Laboratory results**
Methanol	• Visual deficits • Altered mentation	• ↑ Osmolar gap • ↑ Anion gap metabolic acidosis
Ethylene glycol	• Renal failure/flank pain • Altered mentation	• ↑ Osmolar gap • ↑ Anion gap metabolic acidosis • **Calcium oxalate crystals** in urine
Isopropyl alcohol	• Altered mentation	• ↑ Osmolar gap • **No** increased anion gap or metabolic acidosis
Ethanol (ketoacidosis)	• Altered mentation	• ↑ Osmolar gap • ↑ Anion gap metabolic acidosis (ketosis)

Add To New Card | Existing Card

Fomepizole or ethanol

Retinal injury/ blindness

Et

ADH =

©UWo

This patient has altered m
markedly elevated osmola
ingestion is difficult to rule

Ethylene glycol and metha
intentionally ingested (eg,
ethylene glycol and metha

- **Ethylene glycol** me
obstruction.
- **Methanol** metabolit

Fomepizole, a **competiti**
By inhibiting the first step
Alternately, ethanol is som
required.

oxic,

Exhibit Display

Calculated serum osmolality = (2 × serum sodium) + (BUN/2.8) + (glucose/18)

Osmolar gap = measured osmolality − calculated osmolality

©UWorld

Zoom In | Zoom Out | Reset | Add To New Card | Existing Card

- **Methanol** metabolites (eg, formic acid) cause retinal injury that leads to **blindness**.

Fomepizole, a **competitive inhibitor of alcohol dehydrogenase**, is the preferred agent for treatment of ethylene glycol and methanol toxicity. By inhibiting the first step in alcohol metabolism, fomepizole decreases the conversion rate of the parent alcohols into their toxic metabolites. Alternately, ethanol is sometimes used as a competitive inhibitor, although it is less preferred due to difficulty in dosing. Hemodialysis may be required.

(Choice A) Chelators (eg, deferoxamine) bind to heavy metals and form an inert complex that is cleared renally. Heavy metal poisoning often causes gastrointestinal symptoms or neuropsychiatric effects; AGMA (without lactic acidosis) and an elevated osmolar gap are unexpected.

(Choice B) Naloxone competitively binds to opioid receptors in the central nervous system and is used to treat opiate overdose. Patients have sedation and respiratory depression but not an osmolar gap; in addition, hypoxia would be expected on arterial blood gas testing.

(Choice D) Activated charcoal is used to absorb toxins in the stomach and prevent absorption into the body. It is used for a variety of poisonings (eg, phenobarbital, acetaminophen); however, it does not absorb alcohol.

(Choice E) N-acetylcysteine restores hepatic glutathione stores, promoting the enzyme-based detoxification of the toxic acetaminophen metabolite, N-acetyl-p-benzoquinone imine (NAPQI). Acetaminophen toxicity presents with altered mentation and AGMA; however, an elevated osmolar gap is unexpected and patients often develop signs of hepatic failure (eg, jaundice).

Educational objective:
Ethylene glycol and methanol are toxic alcohols that cause anion gap metabolic acidosis and an elevated osmolar gap. Toxicity occurs after metabolization by alcohol dehydrogenase; fomepizole is a competitive inhibitor of alcohol dehydrogenase and is used for the treatment of acute poisoning.

References

- Ethylene glycol or methanol intoxication: which antidote should be used, fomepizole or ethanol?

Pharmacology	Poisoning & Environmental Exposure	Toxic alcohols
Subject	System	Topic

Copyright © UWorld. All rights reserved.

A 12-year-old boy is brought to the emergency department due to a peritonsillar abscess. In preparation for incision and drainage, the patient is given a topical anesthetic, an anxiolytic, pain medications, and antibiotics. He develops a headache and becomes lethargic. Temperature is 38 C (100.8 F), pulse is 110/min, and respirations are 16/min. The lungs are clear to auscultation bilaterally. The lips and fingertips appear blue and the oxygen saturation is 84%. Supplemental oxygen is started but does not improve peripheral oxygen saturation. Which of the following is the most likely cause of this patient's hypoxemia?

A. Bronchial occlusion due to aspiration

B. Carbon monoxide binding to hemoglobin

C. Decreased central respiratory drive

D. Glucose-6-phosphate dehydrogenase deficiency

E. Increased heme iron oxidation

Submit

A 12-year-old boy is brought to the emergency department due to a peritonsillar abscess. In preparation for incision and drainage, the patient is given a topical anesthetic, an anxiolytic, pain medications, and antibiotics. He develops a headache and becomes lethargic. Temperature is 38 C (100.8 F), pulse is 110/min, and respirations are 16/min. The lungs are clear to auscultation bilaterally. The lips and fingertips appear blue and the oxygen saturation is 84%. Supplemental oxygen is started but does not improve peripheral oxygen saturation. Which of the following is the most likely cause of this patient's hypoxemia?

A. Bronchial occlusion due to aspiration (14%)

B. Carbon monoxide binding to hemoglobin (7%)

C. Decreased central respiratory drive (22%)

D. Glucose-6-phosphate dehydrogenase deficiency (12%)

✓ E. Increased heme iron oxidation (41%)

Omitted
Correct answer
E

41%
Answered correctly

02 secs
Time Spent

04/27/2020
Last Updated

Explanation

Acquired methemoglobinemia	
Precipitating factors	• Dapsone • Local/topical anesthetics (eg, benzocaine, teething medications) • Nitrates/nitrites (eg, drinking ground water)

Acquired methemoglobinemia	
Precipitating factors	• Dapsone • Local/topical anesthetics (eg, benzocaine, teething medications) • Nitrates/nitrites (eg, drinking ground water)
Pathophysiology	• Oxidation of heme iron from Fe^{2+} to Fe^{3+} • Fe^{3+} unable to bind oxygen • Oxygen affinity of other hemes increased → left shift → decreased tissue oxygen delivery
Clinical manifestations	• Cyanosis (not improved with supplemental O_2) • Chocolate-brown blood (no color change on exposure to air/oxygen) • Pulse oximetry inaccurate → reads near 85% due to absorption wavelength
Management	• Methylene blue

This patient with cyanosis that does not improve with supplemental oxygen has **acquired methemoglobinemia** due to the **topical anesthetic** (ie, benzocaine). Although methemoglobinemia is most commonly caused by dapsone, the most severe cases are seen after administration of benzocaine, which is found in many throat sprays or teething-relief medications.

Acquired methemoglobinemia occurs when heme **iron atoms** are **oxidized** from the ferrous (Fe^{2+}) to the ferric (**Fe^{3+}**) state. Fe^{3+} heme is **unable to bind to oxygen**; furthermore, the oxygen affinity of the remaining heme moieties in the hemoglobin is increased. This results in a **functional anemia** (due to reduced oxygen binding) and a left shift of the oxygen dissociation curve (due to increased oxygen affinity), which leads to impairment in oxygen delivery despite adequate partial pressure of oxygen in arterial blood. Blood appears chocolate brown and does not change color when exposed to air. Due to the wavelength of light absorbed by Fe^{3+} heme, pulse oximetry converges on 85% as the proportion of methemoglobin increases, regardless of the true oxygen saturation status.

Treatment with **methylene blue** or ascorbic acid reduces iron back to the Fe^{2+} state.

(Choice A) This patient is at risk for bronchial occlusion due to aspiration because of difficulty swallowing (ie, peritonsillar abscess) and medications that impair his ability to protect his airway (ie, pain medication, anxiolytic). However, the lungs would likely sound abnormal, and

benzocaine). Although methemoglobinemia is most commonly caused by dapsone, the most severe cases are seen after administration of benzocaine, which is found in many throat sprays or teething-relief medications.

Acquired methemoglobinemia occurs when heme **iron atoms** are **oxidized** from the ferrous (Fe^{2+}) to the ferric (**Fe^{3+}**) state. Fe^{3+} heme is **unable to bind to oxygen**; furthermore, the oxygen affinity of the remaining heme moieties in the hemoglobin is increased. This results in a **functional anemia** (due to reduced oxygen binding) and a left shift of the oxygen dissociation curve (due to increased oxygen affinity), which leads to impairment in oxygen delivery despite adequate partial pressure of oxygen in arterial blood. Blood appears chocolate brown and does not change color when exposed to air. Due to the wavelength of light absorbed by Fe^{3+} heme, pulse oximetry converges on 85% as the proportion of methemoglobin increases, regardless of the true oxygen saturation status.

Treatment with **methylene blue** or ascorbic acid reduces iron back to the Fe^{2+} state.

(Choice A) This patient is at risk for bronchial occlusion due to aspiration because of difficulty swallowing (ie, peritonsillar abscess) and medications that impair his ability to protect his airway (ie, pain medication, anxiolytic). However, the lungs would likely sound abnormal, and supplemental oxygen would improve cyanosis.

(Choice B) Carbon monoxide binds to hemoglobin with greater affinity than oxygen and also causes a left shift of the oxygen dissociation curve, impairing oxygen delivery to tissues. On pulse oximetry, carboxyhemoglobin reads like oxyhemoglobin, resulting in erroneously high (ie, falsely normal) readings. In addition, this patient does not have exposure risk factors for carbon monoxide (eg, house fire, car exhaust).

(Choice C) Opioid pain medications and benzodiazepine anxiolytics can lead to a decreased central respiratory drive that, if severe, can lead to hypoxia. However, cyanosis would improve with supplemental oxygen.

(Choice D) Medications can precipitate acute hemolysis in patients with glucose-6-phosphate dehydrogenase deficiency. However, it presents with sudden-onset jaundice, pallor, and dark urine; supplemental oxygen would improve pulse oximetry.

Educational objective:
Acquired methemoglobinemia can be precipitated by benzocaine and result in the conversion of Fe^{2+} to Fe^{3+}, which results in functional anemia and a left shift of the oxygen dissociation curve. Patients have cyanosis that does not improve with supplemental oxygen.

References

- Methemoglobinemia in the operating room and intensive care unit: early recognition, pathophysiology, and management.
- Methemoglobinemia related to local anesthetics: a summary of 242 episodes.

benzocaine). Although methemoglobinemia is most commonly caused by dapsone, the most severe cases are seen after administration of benzocaine, which is found in many throat sprays or teething relief medications.

Exhibit Display

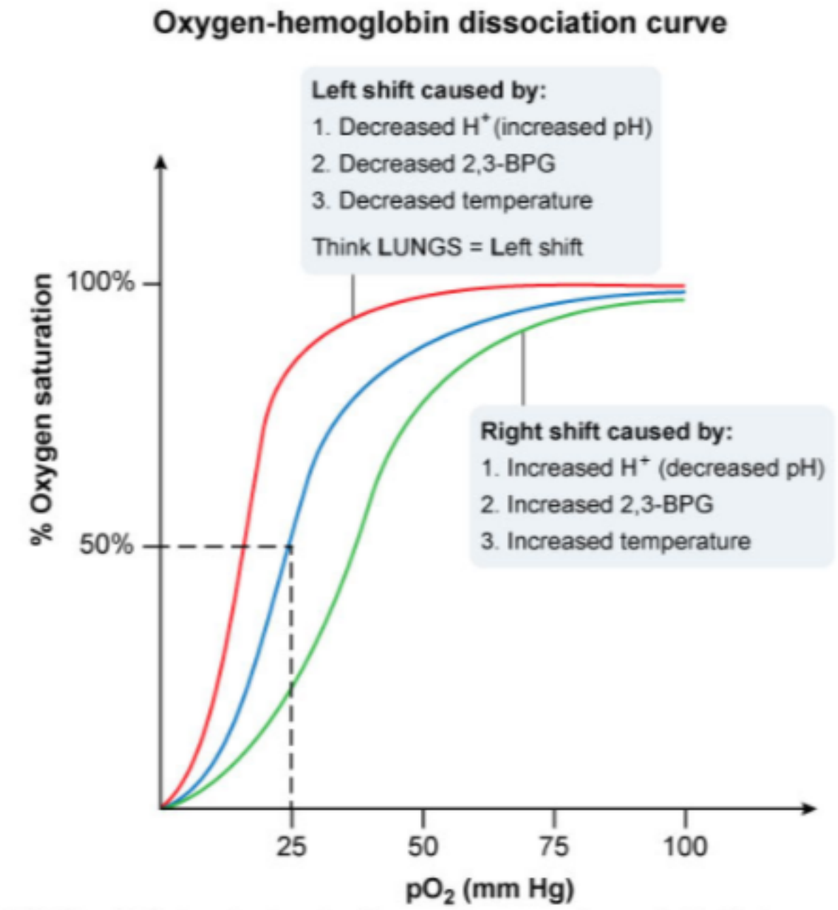

2,3-BPG = 2,3-bisphosphoglycerate; pO_2 = partial pressure of oxygen in the blood.

©UWorld

Zoom In Zoom Out Reset Add To Flash Card

A 14-year-old girl is brought to the emergency department following a suicide attempt. She swallowed several of her grandfather's theophylline tablets after an intense argument with her parents a few hours ago. The patient reports nausea and headache. She has no other prior medical problems and takes no medications. Her temperature is 37 C (98.6 F), blood pressure is 114/76 mm Hg, pulse is 88/min, and respirations are 16/min. This patient should be carefully monitored for which of the following?

A. Hematemesis and melena

B. Hypoglycemia and complete heart block

C. Jaundice and elevated liver enzymes

D. Sedation and respiratory depression

E. Seizures and tachyarrhythmias

Submit

A 14-year-old girl is brought to the emergency department following a suicide attempt. She swallowed several of her grandfather's theophylline tablets after an intense argument with her parents a few hours ago. The patient reports nausea and headache. She has no other prior medical problems and takes no medications. Her temperature is 37 C (98.6 F), blood pressure is 114/76 mm Hg, pulse is 88/min, and respirations are 16/min. This patient should be carefully monitored for which of the following?

A. Hematemesis and melena (1%)

B. Hypoglycemia and complete heart block (9%)

C. Jaundice and elevated liver enzymes (10%)

D. Sedation and respiratory depression (13%)

✓ E. Seizures and tachyarrhythmias (65%)

Omitted
Correct answer
E

65%
Answered correctly

02 secs
Time Spent

03/30/2020
Last Updated

Explanation

In low to moderate doses, methylxanthines cause mild cortical arousal and insomnia, much like caffeine. Acute theophylline intoxication results in nausea/vomiting, abdominal pain, diarrhea, cardiac arrhythmias, and seizures. **Seizures** are the major cause of morbidity and mortality in **theophylline intoxication**. **Tachyarrhythmias** are the other major concern but usually do not cause QT prolongation.

Treatment of theophylline intoxication includes administration of activated charcoal to reduce gastrointestinal absorption. Beta blockers are the drugs of choice for theophylline-induced cardiac tachyarrhythmias. Theophylline-induced seizures are difficult to treat, but benzodiazepines and barbiturates are the most effective agents.

In low to moderate doses, methylxanthines cause mild cortical arousal and insomnia, much like caffeine. Acute theophylline intoxication results in nausea/vomiting, abdominal pain, diarrhea, cardiac arrhythmias, and seizures. **Seizures** are the major cause of morbidity and mortality in **theophylline intoxication**. **Tachyarrhythmias** are the other major concern but usually do not cause QT prolongation.

Treatment of theophylline intoxication includes administration of activated charcoal to reduce gastrointestinal absorption. Beta blockers are the drugs of choice for theophylline-induced cardiac tachyarrhythmias. Theophylline-induced seizures are difficult to treat, but benzodiazepines and barbiturates are the most effective agents.

(Choice A) Iron poisoning can cause hematemesis and melena as iron is directly toxic to gastric mucosal cells.

(Choice B) Bradycardia, hypotension, and hypoglycemia are seen with beta blocker toxicity. Glucagon is the specific antidote as it increases intracellular cyclic adenosine monophosphate and cardiac contractility.

(Choice C) Acetaminophen causes liver damage following a latent period. Acetylcysteine, a glutathione donor, is used to treat acetaminophen toxicity.

(Choice D) Severe sedation, respiratory depression, and constricted pupils are features of opioid intoxication. Treatment includes general supportive care and administration of opioid antagonists such as naloxone.

Educational objective:
Seizures are the major cause of morbidity and mortality from theophylline intoxication. Tachyarrhythmias are the other major concern.

References

- Role of extracorporeal drug removal in acute theophylline poisoning. A review.
- First-line therapy for theophylline-associated seizures.

Pharmacology	Poisoning & Environmental Exposure	Theophyline
Subject	System	Topic

Copyright © UWorld. All rights reserved.

A 49-year-old man with long-standing hypertension comes to the emergency department with severe shortness of breath. He has not been compliant with outpatient follow-up or his prescribed medications. His blood pressure on arrival is 260/144 mm Hg and pulse is 100/min and regular. Chest examination shows bibasilar crackles. There are no heart murmurs. His serum creatinine level is 1.1 mg/dL. Intravenous furosemide and continuous nitroprusside infusion are started along with noninvasive positive pressure ventilation, and he experiences improvement in his symptoms. The next morning, the patient seems confused and lethargic. The nitroprusside infusion rate is found to be higher than recommended. A medication that acts as a donor of which of the following elements would most likely help reverse this patient's condition?

A. Hydrogen
B. Phosphorus
C. Potassium
D. Sodium
E. Sulfur

Submit

A 49-year-old man with long-standing hypertension comes to the emergency department with severe shortness of breath. He has not been compliant with outpatient follow-up or his prescribed medications. His blood pressure on arrival is 260/144 mm Hg and pulse is 100/min and regular. Chest examination shows bibasilar crackles. There are no heart murmurs. His serum creatinine level is 1.1 mg/dL. Intravenous furosemide and continuous nitroprusside infusion are started along with noninvasive positive pressure ventilation, and he experiences improvement in his symptoms. The next morning, the patient seems confused and lethargic. The nitroprusside infusion rate is found to be higher than recommended. A medication that acts as a donor of which of the following elements would most likely help reverse this patient's condition?

A. Hydrogen (19%)
B. Phosphorus (10%)
C. Potassium (10%)
D. Sodium (15%)
✓ E. Sulfur (44%)

Omitted
Correct answer
E

44%
Answered correctly

02 secs
Time Spent

02/25/2020
Last Updated

Explanation

Management approaches to cyanide toxicity	
Treatment strategy	Mechanism of action

Management approaches to cyanide toxicity	
Treatment strategy	**Mechanism of action**
Sodium nitrite	Promotes methemoglobin formation, which combines with cyanide to form cyanmethemoglobin
Sodium thiosulfate	Serves as sulfur donor to promote hepatic rhodanese-mediated conversion of cyanide to thiocyanate, which is excreted in the urine
Hydroxocobalamin	Cobalt moiety binds to intracellular cyanide ions & forms cyanocobalamin, which is excreted in the urine

©UWorld

This patient's clinical presentation is likely due to **cyanide toxicity** from **nitroprusside infusion**. Nitroprusside is a parenteral vasodilator with quick onset/offset mechanics that is commonly used for rapid blood pressure control in patients with hypertensive emergency. It is metabolized in the body to release nitric oxide and cyanide ions.

Cyanide is a potent mitochondrial toxin that binds to Fe^{3+} in **cytochrome c oxidase**, inhibiting the electron transport chain and halting aerobic respiration in the cell. Cyanide toxicity presents with altered mental status, seizures, cardiovascular collapse, **lactic acidosis**, and **bright red venous blood** (seen on venous blood gas and funduscopy). Nitroprusside-induced cyanide toxicity is most likely to occur in patients receiving higher doses/prolonged infusions or those with renal insufficiency.

Cyanide is normally metabolized in the tissues by rhodanese, an enzyme that transfers a sulfur molecule to cyanide to form thiocyanate, which is

©UWorld

This patient's clinical presentation is likely due to **cyanide toxicity** from **nitroprusside infusion**. Nitroprusside is a parenteral vasodilator with quick onset/offset mechanics that is commonly used for rapid blood pressure control in patients with hypertensive emergency. It is metabolized in the body to release nitric oxide and cyanide ions.

Cyanide is a potent mitochondrial toxin that binds to Fe^{3+} in **cytochrome c oxidase**, inhibiting the electron transport chain and halting aerobic respiration in the cell. Cyanide toxicity presents with altered mental status, seizures, cardiovascular collapse, **lactic acidosis**, and **bright red venous blood** (seen on venous blood gas and funduscopy). Nitroprusside-induced cyanide toxicity is most likely to occur in patients receiving higher doses/prolonged infusions or those with renal insufficiency.

Cyanide is normally metabolized in the tissues by rhodanese, an enzyme that transfers a sulfur molecule to cyanide to form thiocyanate, which is less toxic and excreted in the urine. Cyanide overdose depletes the available sulfur donors, allowing cyanide to accumulate in toxic amounts. **Sodium thiosulfate** works as an antidote by providing additional sulfur groups for rhodanese, enhancing cyanide detoxification. It is used in conjunction with **hydroxocobalamin** and **sodium nitrite** in the management of cyanide toxicity.

(Choices A, B, and C) Hydrogen, phosphorous, and potassium have no significant role in the detoxification reactions for cyanide poisoning.

(Choice D) Although sodium thiosulfate contains sodium, the sodium component has no role in the detoxification reaction in cyanide poisoning.

Educational objective:
Cyanide toxicity can occur in patients treated with nitroprusside. Cyanide toxicity presents with altered mental status, seizures, cardiovascular collapse, lactic acidosis, and bright red venous blood. Antidotal treatment of cyanide toxicity can be achieved by 3 different strategies: direct binding of cyanide ions (hydroxocobalamin), induction of methemoglobinemia (sodium nitrite), and use of detoxifying sulfur donors (sodium thiosulfate).

References

- Cyanides.
- Cyanide poisoning caused by ingestion of apricot seeds.

Pharmacology Poisoning & Environmental Exposure Cyanide poisoning

A 6-year-old girl is brought to the emergency department by her parents after they found her unresponsive in the basement. They report that her younger sister sprayed the patient with a bottle that had been filled with pesticide to help rid the house of insects. Temperature is 36.6 C (98 F), blood pressure is 110/60 mm Hg, pulse is 58/min, and respirations are 42/min. On examination, the patient is lethargic and salivating. Which of the following medications should be administered first during treatment of this patient's current condition?

A. Atropine
B. Flumazenil
C. Naloxone
D. Neostigmine
E. Pralidoxime
F. Sodium bicarbonate

Submit

A 6-year-old girl is brought to the emergency department by her parents after they found her unresponsive in the basement. They report that her younger sister sprayed the patient with a bottle that had been filled with pesticide to help rid the house of insects. Temperature is 36.6 C (98 F), blood pressure is 110/60 mm Hg, pulse is 58/min, and respirations are 42/min. On examination, the patient is lethargic and salivating. Which of the following medications should be administered first during treatment of this patient's current condition?

- ✓ A. Atropine (64%)
- B. Flumazenil (0%)
- C. Naloxone (0%)
- D. Neostigmine (4%)
- E. Pralidoxime (29%)
- F. Sodium bicarbonate (1%)

Omitted
Correct answer
A

64%
Answered correctly

02 secs
Time Spent

03/13/2020
Last Updated

Explanation

Organophosphate poisoning	
Common exposures	• Pesticide: farmer/field worker, pediatric ingestion, suicide attempt • Nerve agent: multiple patients presenting with similar symptoms

Organophosphate poisoning	
Common exposures	• Pesticide: farmer/field worker, pediatric ingestion, suicide attempt • Nerve agent: multiple patients presenting with similar symptoms

Manifestations	• Muscarinic:
	  ◦ **D**iarrhea/diaphoresis
	  ◦ **U**rination
	  ◦ **M**iosis
	  ◦ **B**ronchospasms, bronchorrhea, bradycardia
	  ◦ **E**mesis
	  ◦ **L**acrimation
	  ◦ **S**alivation
	• Nicotinic: muscle weakness, paralysis, fasciculations

Management	• Decontamination • Atropine reverses muscarinic symptoms • Pralidoxime reverses nicotinic and muscarinic symptoms (reactivates cholinesterase)

This patient developed bradycardia, tachypnea, and excessive salivation after being exposed to a pesticide, suggesting acute **organophosphate toxicity**. Organophosphates are **acetylcholinesterase inhibitors** that produce signs of **cholinergic excess** due to hyperstimulation of the muscarinic (mnemonic: DUMBELS—see table) and nicotinic (ie, muscle weakness, fasciculations, paralysis) receptors. Most exposures occur with commercial pesticides, typically in farmers/field workers or in children with access to stored chemicals.

Initial management of organophosphate toxicity includes the administration of **atropine**, a **competitive inhibitor** of acetylcholine at the **muscarinic receptor**, which leads to the resolution of muscarinic symptoms (eg, bradycardia, salivation). Patients who exhibit signs of nicotinic hyperstimulation (eg, weakness) should then receive pralidoxime, a cholinesterase-reactivating agent that treats both the muscarinic and nicotinic effects of organophosphates. However, **pralidoxime** should be **given only after atropine** because it can cause transient acetylcholinesterase inhibition, which can momentarily worsen symptoms **(Choice E)**.

This patient developed bradycardia, tachypnea, and excessive salivation after being exposed to a pesticide, suggesting acute **organophosphate toxicity**. Organophosphates are **acetylcholinesterase inhibitors** that produce signs of **cholinergic excess** due to hyperstimulation of the muscarinic (mnemonic: DUMBELS—see table) and nicotinic (ie, muscle weakness, fasciculations, paralysis) receptors. Most exposures occur with commercial pesticides, typically in farmers/field workers or in children with access to stored chemicals.

Initial management of organophosphate toxicity includes the administration of **atropine**, a **competitive inhibitor** of acetylcholine at the **muscarinic receptor**, which leads to the resolution of muscarinic symptoms (eg, bradycardia, salivation). Patients who exhibit signs of nicotinic hyperstimulation (eg, weakness) should then receive pralidoxime, a cholinesterase-reactivating agent that treats both the muscarinic and nicotinic effects of organophosphates. However, **pralidoxime** should be **given only after atropine** because it can cause transient acetylcholinesterase inhibition, which can momentarily worsen symptoms **(Choice E)**.

(Choice B) Flumazenil is indicated to treat benzodiazepine overdose, which presents with sedation but would not be expected to cause bradycardia, tachypnea, or hypersalivation.

(Choice C) Naloxone is indicated for treatment of opioid intoxication, which can cause sedation and miosis but suppresses (not increases) the respiratory rate. Opioid intoxication usually occurs via injection or ingestion, rather than external contact with aerosolized agents.

(Choice D) Neostigmine is another acetylcholinesterase inhibitor that is sometimes used to treat myasthenia gravis; its use would worsen this patient's cholinergic symptoms.

(Choice F) Sodium bicarbonate is indicated to treat patients with tricyclic antidepressant (TCA) overdose who are at risk for ventricular arrhythmias. However, TCA poisoning presents with altered mental status and anticholinergic signs (ie, flushed skin, mydriasis).

Educational objective:
Organophosphates are acetylcholinesterase inhibitors that are commonly used as agricultural pesticides. Toxicity is characterized by signs of cholinergic excess (eg, miosis, bronchospasm, muscle fasciculations/weakness, diarrhea, vomiting, lacrimation). First-line therapy is atropine, a competitive inhibitor of acetylcholine at the muscarinic receptor.

Pharmacology	Poisoning & Environmental Exposure	Organophosphate poisoning
Subject	System	Topic

toxicity. Organophosphates are **acetylcholinesterase inhibitors** that produce signs of **cholinergic excess** due to hyperstimulation of the muscarinic (mnemonic: DUMBELS—see table) and nicotinic (ie, muscle weakness, fasciculations, paralysis) receptors. Most exposures occur with commercial pesticides, typically in farmers/field workers or in children with access to stored chemicals.

Initial management of organophosphate toxicity includes the administration of **atropine**, a **competitive inhibitor** of acetylcholine at the **muscarinic receptor**, which leads to the resolution of muscarinic symptoms (eg, bradycardia, salivation). Patients who exhibit signs of nicotinic hyperstimulation (eg, weakness) should then receive pralidoxime, a cholinesterase-reactivating agent that treats both the muscarinic and nicotinic effects of organophosphates. However, **pralidoxime** should be **given only after atropine** because it can cause transient acetylcholinesterase inhibition, which can momentarily worsen symptoms **(Choice E)**.

(Choice B) Flumazenil is indicated to treat benzodiazepine overdose, which presents with sedation but would not be expected to cause bradycardia, tachypnea, or hypersalivation.

(Choice C) Naloxone is indicated for treatment of opioid intoxication, which can cause sedation and miosis but suppresses (not increases) the respiratory rate. Opioid intoxication usually occurs via injection or ingestion, rather than external contact with aerosolized agents.

(Choice D) Neostigmine is another acetylcholinesterase inhibitor that is sometimes used to treat myasthenia gravis; its use would worsen this patient's cholinergic symptoms.

(Choice F) Sodium bicarbonate is indicated to treat patients with tricyclic antidepressant (TCA) overdose who are at risk for ventricular arrhythmias. However, TCA poisoning presents with altered mental status and anticholinergic signs (ie, flushed skin, mydriasis).

Educational objective:
Organophosphates are acetylcholinesterase inhibitors that are commonly used as agricultural pesticides. Toxicity is characterized by signs of cholinergic excess (eg, miosis, bronchospasm, muscle fasciculations/weakness, diarrhea, vomiting, lacrimation). First-line therapy is atropine, a competitive inhibitor of acetylcholine at the muscarinic receptor.

Pharmacology	Poisoning & Environmental Exposure	Organophosphate poisoning
Subject	System	Topic

Copyright © UWorld. All rights reserved.

A 57-year-old man is brought to the emergency department due to lethargy and altered mental status. His family suspects a suicide attempt. Medical history is significant for dilated cardiomyopathy and major depressive disorder. On arrival, blood pressure is 76/46 mm Hg, pulse is 38/min, and respirations are 16/min. Pupils are 3 mm and reactive. Oropharynx is normal. Examination shows bilateral wheezing. There is no peripheral edema. Capillary refill is 3 seconds. There is no diaphoresis. Which of the following categories of medication did this patient most likely ingest?

A. Beta blocker

B. Cardiac glycoside

C. Opioid

D. Organophosphate

E. Selective serotonin reuptake inhibitor

Submit

A 57-year-old man is brought to the emergency department due to lethargy and altered mental status. His family suspects a suicide attempt. Medical history is significant for dilated cardiomyopathy and major depressive disorder. On arrival, blood pressure is 76/46 mm Hg, pulse is 38/min, and respirations are 16/min. Pupils are 3 mm and reactive. Oropharynx is normal. Examination shows bilateral wheezing. There is no peripheral edema. Capillary refill is 3 seconds. There is no diaphoresis. Which of the following categories of medication did this patient most likely ingest?

- ✓ A. Beta blocker (72%)
- B. Cardiac glycoside (7%)
- C. Opioid (9%)
- D. Organophosphate (6%)
- E. Selective serotonin reuptake inhibitor (2%)

Omitted
Correct answer
A

72%
Answered correctly

02 secs
Time Spent

06/05/2020
Last Updated

Explanation

Medications that cause hypotension & bradycardia	
Medication	**Distinguishing features**
Beta blockers	Hypoglycemia, bronchospasm, heart block

Explanation

Medications that cause hypotension & bradycardia	
Medication	**Distinguishing features**
Beta blockers	Hypoglycemia, bronchospasm, heart block
Calcium channel blockers	Hyperglycemia
Digoxin	Hyperkalemia, "scooped" ST segments on ECG
Clonidine	Miosis, respiratory depression
Cholinergics	SLUD (**S**alivation, **L**acrimation, **U**rination, and **D**efecation)
Magnesium	Hyporeflexia

This patient has altered mental status and difficulty breathing in the setting of **hypotension** and **bradycardia**. The body typically compensates for hypotension by becoming tachycardic. It is unusual to see both bradycardia and hypotension simultaneously, and **medication overdose** should be suspected in these cases.

Although several medications can cause hypotension and bradycardia, this patient's **wheezing** suggests **bronchospasm** and makes **beta blocker toxicity** most likely. Beta-1 receptors are located primarily in the heart, whereas **beta-2 receptors** are located on the smooth muscle of the lung **bronchioles** and skeletal muscle arterioles, as well as on hepatocytes. When activated by catecholamines, beta-1 receptors cause increased heart rate and cardiac contractility and beta-2 receptors cause smooth muscle relaxation with bronchodilation. Beta-2 receptor activation also stimulates hepatocellular gluconeogenesis and glycogenolysis to increase blood glucose.

Beta blockers are commonly used to treat high blood pressure and arrhythmias, and often target both beta-1 and beta-2 receptors. Because beta blockers act as **competitive antagonists for endogenous catecholamines**, beta blocker toxicity prevents the catecholamine-mediated effects on the heart, lungs, and liver, causing hypotension, bradycardia, bronchospasm, and **hypoglycemia**. The hypotension (ie, poor organ perfusion) and hypoglycemia contribute to altered mental status.

increased heart rate and cardiac contractility and beta-2 receptors cause smooth muscle relaxation with bronchodilation. Beta-2 receptor activation also stimulates hepatocellular gluconeogenesis and glycogenolysis to increase blood glucose.

Beta blockers are commonly used to treat high blood pressure and arrhythmias, and often target both beta-1 and beta-2 receptors. Because beta blockers act as **competitive antagonists for endogenous catecholamines**, beta blocker toxicity prevents the catecholamine-mediated effects on the heart, lungs, and liver, causing hypotension, bradycardia, bronchospasm, and **hypoglycemia**. The hypotension (ie, poor organ perfusion) and hypoglycemia contribute to altered mental status.

(Choice B) Although cardiac glycoside (eg, digoxin) toxicity causes hypotension and bradycardia, bronchospasm is not seen. Toxicity also presents with nausea, vomiting, tachyarrhythmias, and visual changes.

(Choice C) Opioid overdose presents with respiratory depression, depressed mental status, and pinpoint pupils. Bronchospasm is not typically seen. In fact, opioids help suppress cough receptors.

(Choice D) Although organophosphate toxicity can cause bronchorrhea/bronchospasm and bradycardia, clinical features are dominated by other findings of cholinergic excess (eg, salivation/drooling, lacrimation, diaphoresis); pupils are also usually constricted.

(Choice E) Serotonin syndrome primarily manifests with neuromuscular hyperactivity (ie, tremor, muscle rigidity, myoclonus, hyperreflexia). Bronchospasm is uncommon.

Educational objective:
Beta blockers act as competitive antagonists for endogenous catecholamines; therefore, toxicity presents with hypotension, bradycardia, bronchospasm, and hypoglycemia. The hypotension and hypoglycemia contribute to altered mental status.

References

- Beta-Blocker Toxicity

Pharmacology	Poisoning & Environmental Exposure	Beta blocker poisoning
Subject	System	Topic

Copyright © UWorld. All rights reserved.